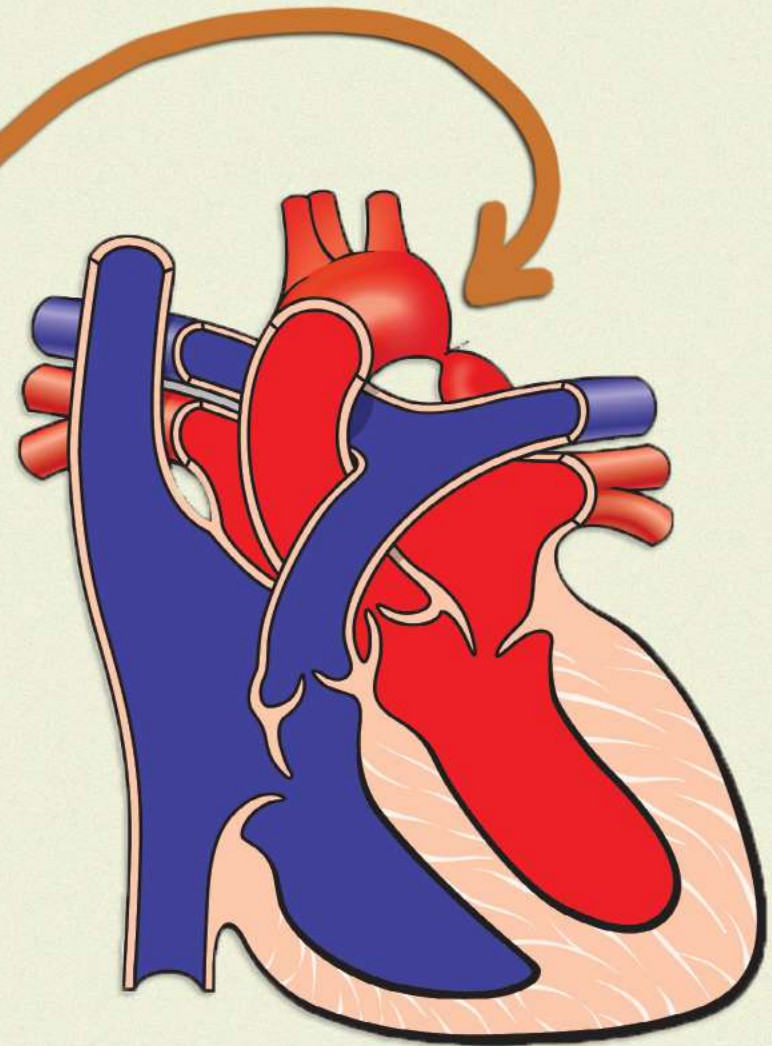


Coarctation of Aorta



Coarctation of Aorta

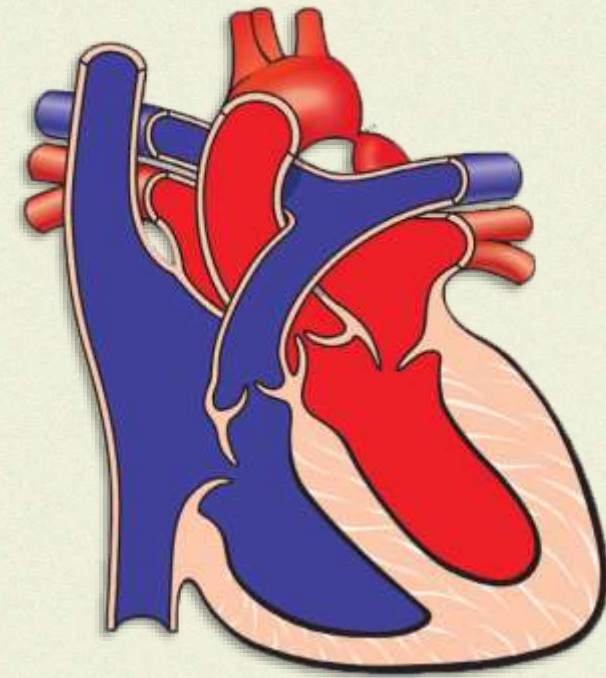
Congenital narrowing of descending aorta

Location - Usually distal to origin of Left Subclavian Artery

Commonly in Boys

Associations with other congenital abnormalities - Bicuspid aortic valve & Turner's syndrome

Shall be excluded as a cause for *secondary hypertension in young people* with high blood pressure



Coarctation of Aorta

Signs

Pulse

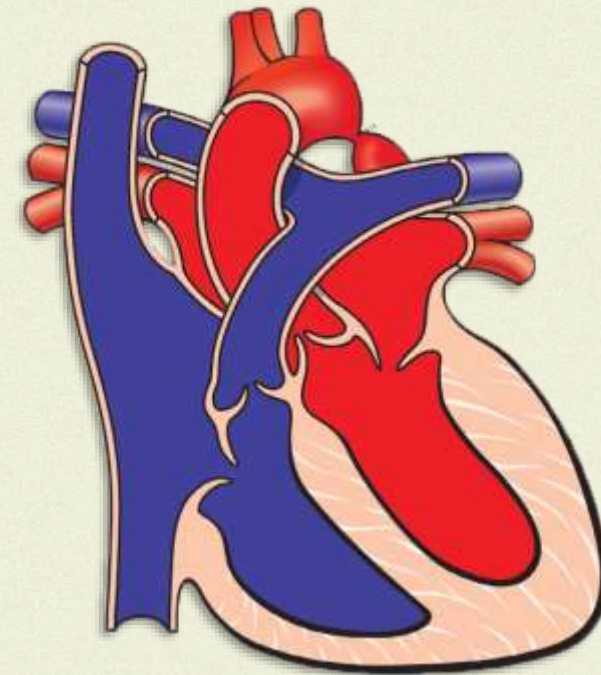
- Radio-femoral delay
- weak femoral pulse

BP – Raised

Auscultation

- Scapular bruit
- Systolic murmur, best heard over the left scapula

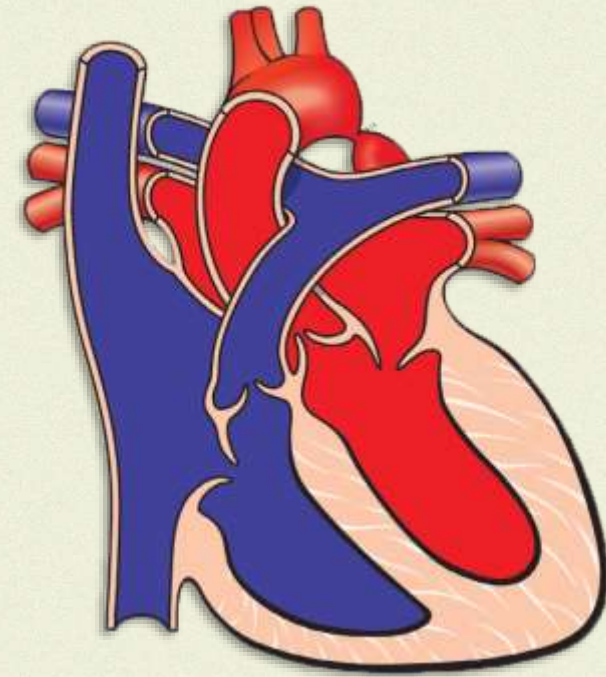
Cold lower extremities



Coarctation of Aorta

Complications

1. Heart Failure
2. Infective Endocarditis
3. Intracerebral Hemorrhage



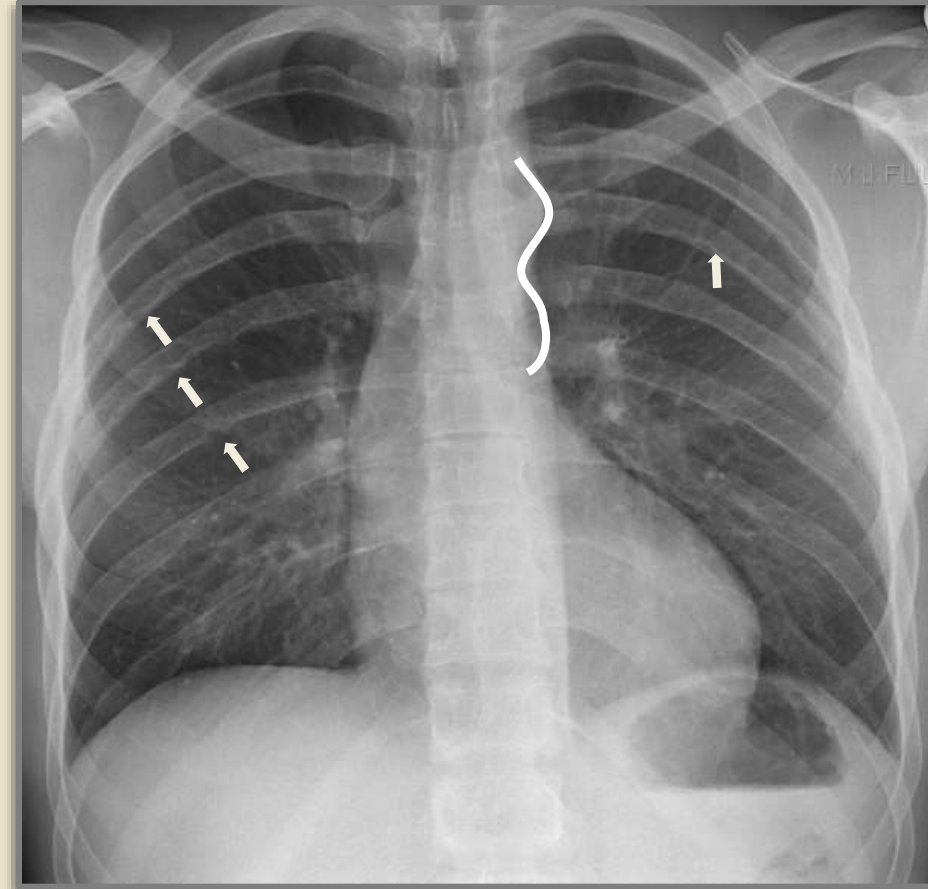
Coarctation of Aorta

Investigations

1. Chest X-Ray

- 3rd - 9th Rib notching
- 3-Sign in aortic knuckle region

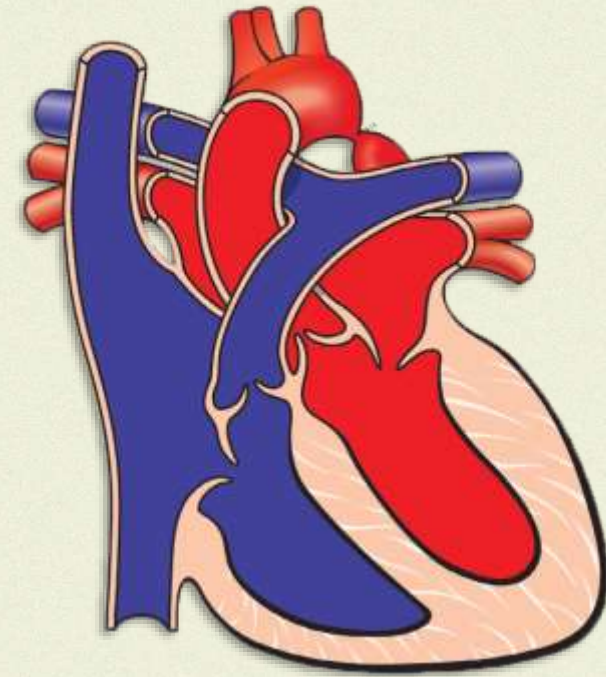
2. CT or MR- Aortogram



Coarctation of Aorta

Treatment

1. Balloon dilatation +/- Stent
2. Surgery





Last Second **Medicine**

[Like](#) | [Share](#) | [Subscribe](#)

