

A green ribbon graphic with a white outline, tilted diagonally. It has a central rectangular area containing the text 'Learn Now' in yellow.

Learn  
Now

# Giant Cell Arteritis

Clinical Features, Investigations &  
Treatment

# Giant Cell Arteritis

Clinical Features, Investigations &  
Treatment

# Introduction

- **Large vessel** Arteritis
- Granulomatous
- ~ Temporal Arteritis
- Rare under 60 years
- Male to Female ratio – 3:1
- Polymyalgia Rheumatica (PMR) – 50%

# Clinical Features

## Cranial

- Headache
- Temporal artery tenderness
- Scalp tenderness
- Tongue / Jaw claudication
- Amaurosis fugax
- Unilateral blindness
- Irreversible bilateral visual loss

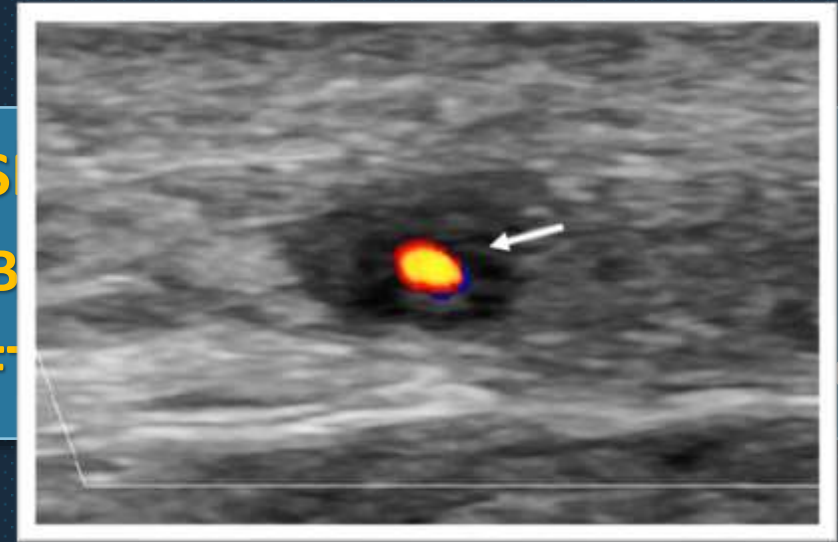
## Extra-cranial

- Malaise
- Weight loss
- Fatigue
- Night sweats
- Morning stiffness
- Unequal or weak pulses

# Investigations

- **Temporal Artery Biopsy**
  - Diagnostic
  - 10% cases – Negative biopsy
- **Temporal Artery Doppler Ultrasound**
  - Halo sign
- **FDG-PET scan**

- ESR
- CRP
- LFT



# Treatment

## - **Corticosteroids – Mainstay of treatment**

- Prednisolone
- IV Methylprednisolone - Evolving visual loss  
or history of Amaurosis fugax

## - **Supportive treatment** with Steroids

- PPI
- Bisphosphonates
- Cholecalceferol and Calcium
- Aspirin

# Prognosis

**2-year course, then remission**

Like | Share | Subscribe

Last Second  
**Medicine**